

## ***Anesthesia in Patient with Left Ventricular Assist Device LVAD support. A Case Report.***

Saimir KUCI\*, Alfred IBRAHIMI, Ermal LIKAJ, Marsela GOGA,  
Ervin BEJKO, Stavri LLAZO, Jacob ZEITANI

Received: 10 November 2019 / Accepted: 25 November 2019 / Published online: 20 July 2020  
© The Author(s) 2020. This article is published with open access at <https://journal.astes.org.al>

### ***Abstract***

**Background:** Left ventricular assist device (LVAD) implantation is not only a bridge-to-transplantation option for patients awaiting a donor heart, but is often used as bridge-to-destination therapy in patients unsuitable for transplantation for various reasons. Device infection remains a threatening complication, which may lead to prolonged hospitalization, need to device exchange, urgent transplantation, and even death of the patient. Infections with multidrug resistant (MDR) organisms pose major difficulties for eradication therapy. Especially patients who are subject to continuous hospital treatments risk contamination or change of resistances spectrum. Gold standard therapy of certain organisms often fails to eradicate surface associated colonization's of implanted devices such as cardiovascular implants, while failed eradication leads to numerous complications and an increased mortality rate among the affected patients. Device infections through multidrug resistant bacteria, such as MRSA, are often resistant even to first-line antibiotics, due to extended resistance spectrum and reduce tissue penetration in scar tissue after multiple surgical procedures. In addition, a solid biofilm on devices is often impenetrable even for suitable antibiotics because of the isolating nature of biofilms.

**Case presentation:** A 48-year-old patient 72 kg, height 172 cm with dilated cardiomyopathy, his course was complicated by pump failure requiring LVAD HeartMate III placement 3 years (Milan Italy). The parameters of the LVAD pump were determined for the patient from the moment of the Pump speed 5300 rpm Flow 4.4 lpm was set. The patient performed moderate activity under normal conditions. The patient regularly took Coumadin to keep the recommended INR levels at the recommended target values 2.5. At the site of the exit of the cavity from the skin in the region of the right hypochondrium, there was an infection that for a long time was treated with various schemes with ambulatory antibiotics

**Conclusions:** In the present case we showed that successful eradication of a chronic LVAD driveline infection was only possible when approached both surgically and conservatively. It is important to note that a good knowledge of the physiopathology of heart failure, the widest possible information on the treatment of heart failure with the help of LVAD implantation is very important in the treatment and survival of these patients.

**Keywords:** LVAD, transplantation, infections, heart failure, resistant bacteria

### ***Introduction***

Left ventricular assist device (LVAD) implantation is not only a bridge-to-transplantation option for patients awaiting a donor heart, but is often used as bridge-to-destination therapy in patients unsuitable for transplantation for various reasons. Device infection remains a threatening complication, which may lead to prolonged hospitalization, need to device exchange, urgent transplantation, and even death of the patient. Infections with multidrug resistant (MDR) organisms pose major difficulties for eradication therapy. Especially patients who are subject to continuous hospital treatments risk contamination or change of resistances spectrum. Gold standard therapy of certain organisms often fails to eradicate surface associated

Original article, no submission or publication in advance or in parallel

\* **Corresponding author:**  
Saimir KUÇI MD, PhD  
✉ [saimirkuci@gmail.com](mailto:saimirkuci@gmail.com)

Department of Anesthesiology and Reanimation, German Hospital  
International Tirana, ALBANIA

colonization's of implanted devices such as cardiovascular implants, while failed eradication leads to numerous complications and an increased mortality rate among the affected patients. Device infections through multidrug resistant bacteria, such as MRSA, are often resistant even to first-line antibiotics, due to extended resistance spectrum and reduce tissue penetration in scar tissue after multiple surgical procedures. In addition, a solid biofilm on devices is often impenetrable even for suitable antibiotics because of the isolating nature of biofilms.

### LVAD Physiopathology

Treatment of severe heart failure with a continuous flow through the LVAD ventricular assistance system is spreading worldwide due to minor adverse side effects, improved outcomes, and acceptance of therapy (1.3). Although most patients supported by an LVAD have resulted in prolonged survival and quality of life has improved, elderly patients and those with comorbidities have a high risk of complications (4.5). Gastrointestinal bleeding has emerged as a side effect in patients with LVAD support with continuous flow (6.8), while right heart failure, infection, STROKE and pump thrombosis continue to be associated complications with considerable morbidity and mortality (9.12). Given that patients will present co-morbidities at the time they seek sustainable LVAD support, and many will seek such support for long periods, technological improvements that address hemocompatibility can help reduce the frequency and severity of these side effects. Continuous axial flow and centrifugal flow LVAD pump blood through narrow flow pathways, which contributes to hemolysis, platelet activation, and von Willebrand factor impairment (vWF) (13.17).

### Device Description

The new centrifugal-flow LVAS is intended to provide long-term hemodynamic support in patients with advanced HF. This device is designed for intrapericardial placement, with an inflow conduit inserted into the LV and the outflow graft attached to the ascending aorta (Fig 1). A fully magnetically levitated (Full MagLev) rotor with large blood-flow paths (0.5 mm along the side and 1.0 mm above and below the rotor) minimizes shear forces, which is expected to reduce detrimental effects on blood components (18). This rotor design avoids the need for mechanical bearings, reducing wear of the moving component and heat generation within the pump.

The device's internal surfaces are textured with titanium microspheres to promote adhesion of patient cells for reduced thrombogenicity. Operating in an artificial-pulse mode, the LVAS's rotor changes speed every 2 s to generate pulsatile flow. The pump operates at rotor speed in the range of 3,000 to 9,000 rpm, and the maximum flow rate is 10 l/min. The pump motor receives power from a pair of 14V lithium-ion batteries or external AC power sources.

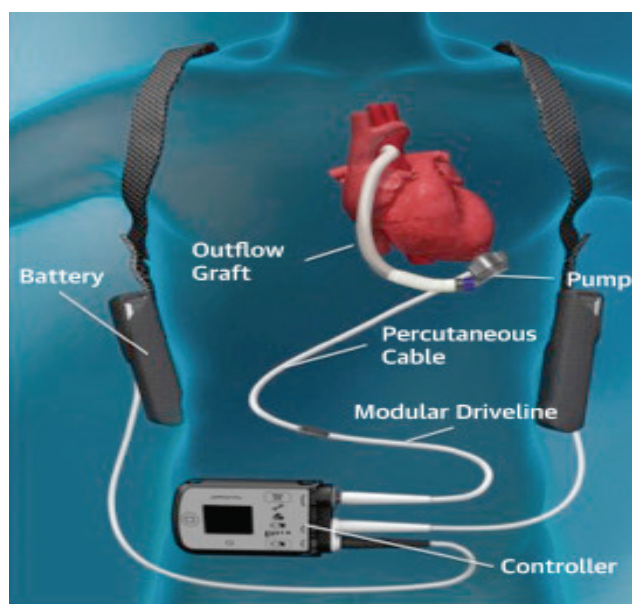


Fig.1. Heartmate 3

### Implantation

LVAS implantation is accomplished by standard median sternotomy and cardiopulmonary bypass techniques. The apical cuff is sewn to the epicardial surface near the apex of the LV, and a myocardial core is created through the cuff with a circular knife. The outflow graft is anastomosed to the ascending aorta in the standard fashion. The pump is positioned at the apex of the LV; the inflow conduit is inserted into the LV through the apical opening and then secured by the apical cuff. The pump power cable is tunneled and externalized through the abdominal wall and connected to a modular cable. The modular cable is attached to the power and control system. Once the outflow graft and pump are de-aired, cardiopulmonary bypass flow is decreased, and the pump is turned on at 3,000 rpm. Following separation from cardiopulmonary bypass, ramped speed tests are performed to determine a constant speed setting. Anticoagulation guidelines include post-operative intravenous heparin to achieve a partial thromboplastin time of 45 to 65 s.

### Case Report

A 48-year-old patient 72 kg, height 172 cm with dilated cardiomyopathy, his course was complicated by pump failure requiring LVAD HeartMate III placement 3 years (Milan Italy). The parameters of the LVAD pump were determined for the patient from the moment of the implantation: Pump speed 5300 rpm Flow 4.4 lpm was set. The patient performed moderate activity under normal conditions. The patient regularly took Coumadin to keep the recommended INR levels at the recommended target values 2.5. At the site of the exit of the cavity from the skin in the region of the right hypochondrium, there was an infection

that for a long time was treated with various schemes with ambulatory antibiotics (Fig.2):

Initially with Ceftriaxone (IM) according to the antibiogram for positive culture against *Staphylococcus* spp in June 2019. In the following months the patient is presented again in hospital with positive wound culture for *Pseudomonas aeruginosa*. It is tried to be treated on an outpatient basis according to the antibiogram with Ciprofloxacin but no significant improvements were seen in the follow up. The patient is hospitalized and the culture is positive for *Pseudomonas Aeruginosa*.

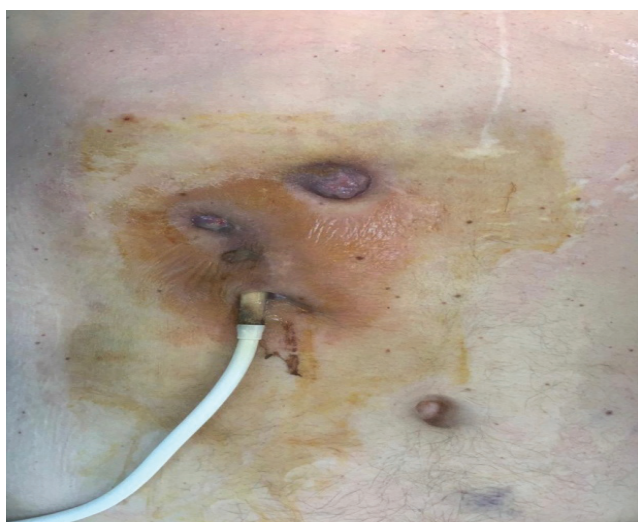

Fig.2. Infection on cable insertion

A treatment regimen with double antibiotic therapy IV: Tazocine and Ceftriaxone was prescribed. After a week of treatment with antibiotics prescribed by the antibiogram, it was found that the healing of the infected wound was not progressing.

Under these conditions it was decided to perform a surgical procedure to move the battery cable to an uninfected area. During the surgical intervention, locoregional anesthesia with lidocaine and potentiation with endovenous propofol and fentanyl anesthesia were applied. Patient monitoring was EKG, SpO<sub>2</sub>, IBP, catheter placement in the right femoral artery to monitor the patient as radial artery cannulation was impossible due to lack of pulsating flow. At the time of arterial canulation the BP was 87 mmHg on average, at the time of cavitory rupture it was seen that the BP started with a diastolic systolic curve of 70/33 mmHg with a BP between 46 mmHg. At the moment when the battery cable was connected and the Assist Device was put into operation, the curves changed from systolic diastolic to constant pressure curves with an average BP of 54 mmHg as in the following figure. (Fig.3)

The hemodynamic were stable throughout the intervention. The debit of the LVAD pump was good, providing a satisfactory perfusion with an average

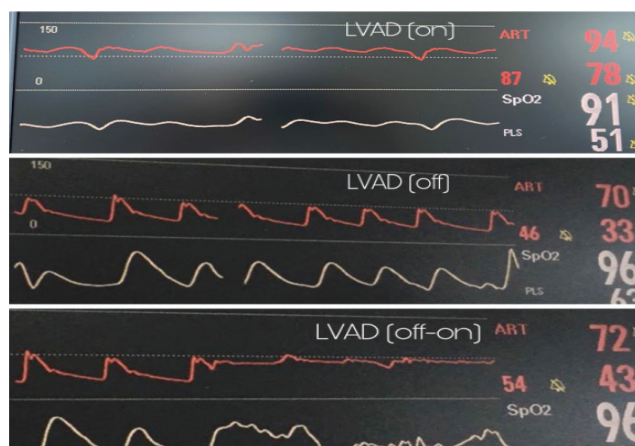

Fig.3 LVAD on-off-on

pressure above 60 mmHg during anesthesia, and the use of recommended vasopressor drugs was required in this case.

The surgical intervention lasted 60 min and the awakening was immediate.

The patient is discharged from after 15 days of stay with negative cultures of the tube insertion wounds and good conditions.

## Conclusions

In this case, we showed that the successful elimination of a chronic infection of the cavernous outlet of the LVAD device in our patient was possible only when treated both surgically and conservatively. It is important to note that a good knowledge of the physiopathology of heart failure, the widest possible information on the treatment of heart failure with the help of LVAD implantation is very important in the treatment and survival of these patients. It should be noted that during anesthesia the necessary monitoring should be done to obtain information as soon as possible and to prevent any possible complications. This is a single case study, from which conclusions can be drawn towards broader applications. Especially in patients with co-morbidities suffering from chronic infections from foreign material, a similar aggressive approach to infection eradication may be attempted, in order to avoid even the most aggressive redo operations.

**COI Statement:** This paper has not been submitted in parallel. It has not been presented fully or partially at a meeting or podium or congress. It has not been published nor submitted for consideration beforehand.

All authors declare that there is no conflict of interest. **This research received no specific grant from any funding agency in the public, commercial, or nonprofit sectors.** There are no relevant or minor financial relationships from authors, their relatives or next of kin with external companies.

**Disclosure:** The authors declared no conflict of interest. No funding was received for this study.



## References

1. Starling RC, Naka Y, Boyle AJ, et al. Results of the post-U.S. Food and Drug Administration-approval study with a continuous-flow left ventricular assist device as a bridge to heart transplantation: a prospective study using the INTERMACS (Interagency Registry for Mechanically Assisted Circulatory Support). *J Am Coll Cardiol* 2011; 57: 1890–8.
2. John R, Kamdar F, Liao K, Colvin-Adams M, Boyle A, Joyce L. Improved survival and decreasing incidence of adverse events with the HeartMate II left ventricular assist device as bridge-to-transplant therapy. *Ann Thorac Surg* 2008; 86: 1227–34, discussion 1234–5.
3. John R, Naka Y, Smedira NG, et al. Continuous flow left ventricular assist device outcomes in commercial use compared with the prior clinical trial. *Ann Thorac Surg* 2011; 92: 1406–13, discussion 1413.
4. Cowger J, Sundareswaran K, Rogers JG, et al. Predicting survival in patients receiving continuous flow left ventricular assist devices: the HeartMate II risk score. *J Am Coll Cardiol* 2013; 61: 313–21.
5. Schaffer JM, Allen JG, Weiss ES, et al. Evaluation of risk indices in continuous-flow left ventricular assist device patients. *Ann Thorac Surg* 2009; 88: 1889–96.
6. Crow S, John R, Boyle A, et al. Gastrointestinal bleeding rates in recipients of nonpulsatile and pulsatile left ventricular assist devices. *J Thorac Cardiovasc Surg* 2009; 137: 208–15.
7. Morgan JA, Paone G, Nemeh HW, et al. Gastrointestinal bleeding with the HeartMate II left ventricular assist device. *J Heart Lung Transplant* 2012; 31: 715–8.
8. Harvey L, Holley CT, John R. Gastrointestinal bleed after left ventricular assist device implantation: incidence, management, and prevention. *Ann Cardiothorac Surg* 2014; 3: 475–9.
9. Mehra MR, Stewart GC, Uber PA. The vexing problem of thrombosis in long-term mechanical circulatory support. *J Heart Lung Transplant* 2014; 33: 1–11.
10. Yuan N, Arnaoutakis GJ, George TJ, et al. The spectrum of complications following left ventricular assist device placement. *J Card Surg* 2012; 27: 630–8.
11. Takeda K, Naka Y, Yang JA, et al. Outcome of unplanned right ventricular assist device support for severe right heart failure after implantable left ventricular assist device insertion. *J Heart Lung Transplant* 2014; 33: 141–8.
12. Nienaber JJ, Kusne S, Riaz T, et al. Clinical manifestations and management of left ventricular assist device-associated infections. *Clin Infect Dis* 2013; 57: 1438–48.
13. Crow S, Chen D, Milano C, et al. Acquired von Willebrand syndrome in continuous-flow ventricular assist device recipients. *Ann Thorac Surg* 2010; 90: 1263–9, discussion 1269.
14. Baghai M, Heilmann C, Beyersdorf F, et al. Platelet dysfunction and acquired von Willebrand syndrome in patients with left ventricular assist devices. *Eur J Cardiothorac Surg* 2015; 48: 421–7.
15. Hasin T, Deo S, Maleszewski JJ, et al. The role of medical management for acute intravascular hemolysis in patients supported on axial flow LVAD. *ASAIO J* 2014; 60: 9–14.
16. Slaughter MS, Sobieski MA 2nd, Graham JD, Pappas PS, Tatroles AJ, Koenig SC. Platelet activation in heart failure patients supported by the HeartMate II ventricular assist device. *Int J Artif Organs* 2011; 34: 461–8.
17. Meyer AL, Malehsa D, Bara C, et al. Acquired von Willebrand syndrome in patients with an axial flow left ventricular assist device. *Circ Heart Fail* 2010; 3: 675–81.
18. Schmitto JD, Hanke JS, Rojas SV, Avsar M, Haverich A. First implantation in man of a new magnetically levitated left ventricular assist device (HeartMate III). *J Heart Lung Transplant* 2015; 34: 858–60.