

Benign Glomus Tumor of the Urinary Bladder: A Case Report and Literature Review.

Lutfi Alia ^{1*}, Teona Bushati ², Leart Berdica ², Ledi Bardhi ³, Sergio A Tripodi ³

Received: 4 June 2025 / Accepted: 15 June 2025 / Published online: 20 July 2025

This article is published with open access at <https://journal.astes.org.al>

© The author(s) 2025. © The Albanian Journal of Trauma and Emergency Surgery is an Open Access Journal. All articles are distributed under the terms of the Creative Commons Attribution Non-Commercial License: <http://creativecommons.org/licenses/by-nc> which permits unrestricted non-commercial use, distribution, and reproduction in any medium provided the original work is properly cited.

Abstract

Introduction: Glomus tumors (GT) are sporadic mesenchymal neoplasms found in adults, comprising less than 2% of soft tissue tumors. GT originates from glomocytes, which are modified vascular smooth muscle cells located in the walls of specialized structures of the glomus body—a neuromyoarterial plexus in the dermis of the skin that typically plays a role in thermoregulation. Most GTs are benign, though some cases exhibiting atypical or malignant behavior have been documented. GT usually occurs in the skin and superficial soft tissues, primarily in the extremities, especially beneath the nail bed, and rarely affects internal organs; however, those organs lack glomus bodies. The occurrence of GT in the urinary bladder, which does not contain glomus bodies, is an infrequent occurrence and has been reported sporadically. The gene implicated in the pathogenesis of bladder GT is the glomulin gene (GLMN), situated on chromosome arm 1p21-22. Multiple subungual granular tumors (GTs) have been reported in neurofibromatosis type 1, originating from a mutation in the NF1 gene.

The first case of benign GT of the urinary bladder was described by Tripodi SA et al. in 2013, while malignant GT of the urinary bladder was described by Shim HS et al. in 2005. Depending on the relative prominence of glomus cells, vascular structures, and smooth muscle, the GTs are subcategorized: Solid histotype, Glomangioma, and Glomangiomyoma.

In this study, we report a case of benign GT of the urinary bladder in a 63-year-old man presenting with recurrent hematuria of unknown etiology. The cystoscopy showed a polypoid lesion at the anterior wall of the urinary bladder. The transurethral resection was performed, and the lesion was easily removed. In the microscopic examination of the biopsy, the final pathological diagnosis was a benign glomus tumor of the urinary bladder – a solid histotype. After resection of GT, the patient was followed according to standard follow-up protocol for patients with bladder tumors. One year after resection, the patient was in good health, with no recurrence or metastasis, demonstrating the successful treatment and follow-up of this rare case.

Conclusions: GTs arising in the bladder are extremely rare. It is challenging to diagnose bladder GTs based on their clinical features. The gold standard method for diagnosing GT is histopathological examination and immunohistochemical analysis. Transurethral resection is the most common treatment used for benign or atypical bladder GT. However, it should also be considered in the differential diagnosis for Bladder neoplasms.

Keywords: Glomus tumors, Urinary bladder, Glomangioma, Glomangiomyoma.

Original article, no submission or publication in advance or in parallel

* **Corresponding author:**
Prof. Lutfi Alia, MD, PhD
✉ alia.lutfi@yahoo.com

1 Centre of Oncological Prevention, Siena, ITALY

2 Department of Pathology, Faculty of Medicine, University of Medicine,
Tirana, ALBANIA.

3 Department of Pathology and Oncology, University of Siena, ITALY

Introduction

GTs represent about 2 % of soft tissue tumors, which occur in both sexes with equal frequency, between 40 - 85 years. [1, 2, 3, 4] Most of the GTs are benign, but some atypical/malignant cases have been reported. [3, 4, 5, 6, 7, 8] GTs most often occur in the extremities, typically in the subungual region of the fingers, where glomus bodies are abundant, specialized structures engaged in thermoregulation. Approximately 10% of these GTs are multiple. [2, 3, 9, 10, 11, 12]

GTs are rare in the internal organs because those organs usually do not have glomus bodies. GT is described in different organs as the urinary (kidney, pelvis, bladder, urethra) [3, 4, 9 – 16] and the prostate [17]. The reproductive organs (uterine cervix, ovary, testis) [18], the digestive (esophagus, stomach, intestine, liver) [19, 20], the cardiovascular (heart, carotid artery) [21], the endocrine glands (thyroid, breast) [22], the nervous system (sciatic nerve) [2, 6], the mesentery. [23]

The bladder is an unusual location for a glomus tumor, as neither glomus bodies nor ectopic glomus cells have ever been described in the bladder. [3, 4, 5, 8, 9]

The first case of benign glomus tumor of the urinary bladder was described by Tripodi et al. in 2013. [3, 7, 9]

Depending on the relative prominence of glomus cells, vascular structures, and smooth muscle, GTs are subcategorized: solid histotype (75 % of cases), Glomangioma, and glomangiomyoma. [3, 6, 7]

Morphologically, benign solid GT of the urinary bladder is composed of glomus cells (neuromyo-arterial cells), blood vessels, modified vascular smooth muscle cells present in the walls, and some myxoid and hyalinized areas of the stroma. Tumor cells clustered around thin, branching, and dilated vessels. [2, 3, 7, 9]

The gene involved in the pathogenesis of GT of the urinary bladder is the globulin gene (*GLMN*), located on the short arm of chromosome 1 at 1p21-22. This gene has a secondary truncating mutation.[3]

Shim HS has previously described the first case of a malignant glomus tumor of the urinary bladder.[4] The malignant GT presents with large dimensions, cytologic atypia, a high mitotic rate, necrosis, and infiltration of the muscle. The patient died 2 months later from multiple pulmonary metastases.[4]

Grade of malignancy GT was determined using the criteria, including marked nuclear pleomorphism, mitotic activity, or the presence of atypical mitotic figures. [24]

Report of Case

Herein, we report a case of benign glomus tumor of the urinary bladder, diagnosed in a 63-year-old male smoker with recurrent haematuria of unknown etiology. The patient suffered from arterial hypertension. He did not report any urinary symptoms. Physical examination showed no abnormal findings. Blood cell counts and results of biochemical tests were within the reference range. A urinalysis displayed haematuria. The bladder ultrasound showed an avascular and homogeneous isoechoic polypoid mass with a maximum diameter of 12 mm at the anterior wall of the urinary bladder.

An endoscopic examination of the bladder showed a polypoid lesion with a smooth surface located in the anterior wall of the bladder. A transurethral resection was performed, and the lesion was easily removed. The surgical specimen consisted of 3 firm-to-hard, whitish fragments ranging from 5 - 7 mm. In the microscopic examination of the biopsy,

the pathological diagnosis is Benign Glomus Tumor of the Bladder - solid histotype.

After the resection of the tumor, our patient was followed according to standard follow-up protocol for patients with bladder tumors. One year after resection of GT, the patient was in good health without recurrence or metastasis.

Pathologic Findings

Microscopic examination at low power showed a well-circumscribed, not encapsulated, neoplasm covered by a thin layer of normal urothelium with some von Brun nests. Some areas presented an organoid or epithelioid pattern characterized by nests of neoplastic cells. The neoplastic cells had a monotonous appearance, lacking well-defined cell borders, and exhibited abundant light eosinophilic cytoplasm and round to oval, bland nuclei without nucleoli. Atypia, mitoses, intravascular growth, and necrosis were absent. (Figure 1). In other areas, tumor cells clustered around thin, branching, and dilated vessels (Figure 2). The stroma presented myxoid areas and hyalinized areas (Figure 2).

Immunohistochemically, the neoplastic glomus cells were negative for CK 20, CK AE1/AE3, and p63, whereas these markers extensively stained superficial urothelium and von Brun nests. In contrast, the same neoplastic cells strongly expressed Smooth Muscle α -Actin (Figure 3) and vimentine. Marker CD34 is expressed in capillary endothelial cells and lightly expressed in glomus cells of myxoid areas (Figure 4). Type IV collagen stained the cell membrane of individual glomus cells, showing a “chicken-wire” network of matrix present between these cells (Figure 5). The proliferation index with Monoclonal Antibody MIB-1 for the nuclear antigen Ki - 67 was less than 5 % (Figure 6). Other markers, such as desmin, synaptophysin, chromogranin, and S-100 protein, did not stain the neoplastic cells of GT.

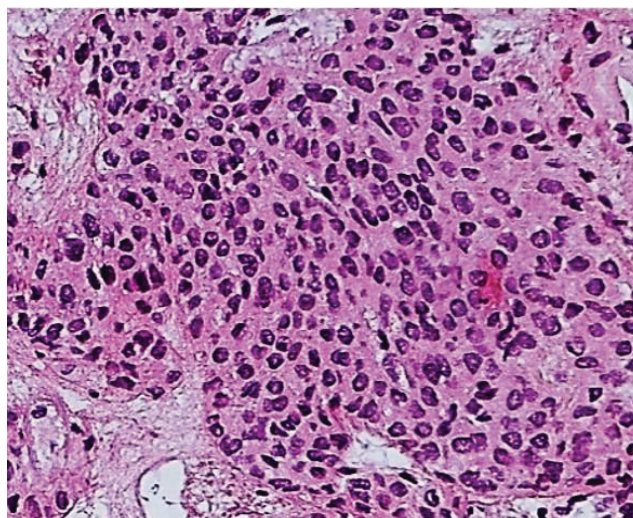


Figure 1. Nests of monomorphic cells, with bland nuclei and eosinophilic cytoplasm

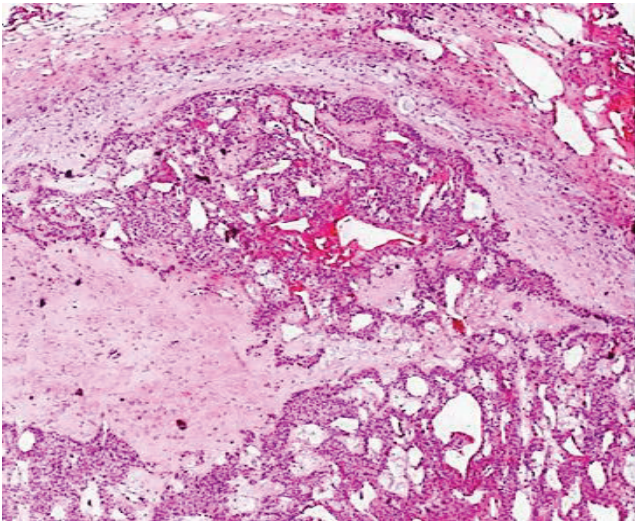


Figure 2. The tumor stroma presented myxoid, and hyalinized areas, covered urothelium with some von Brun nests.

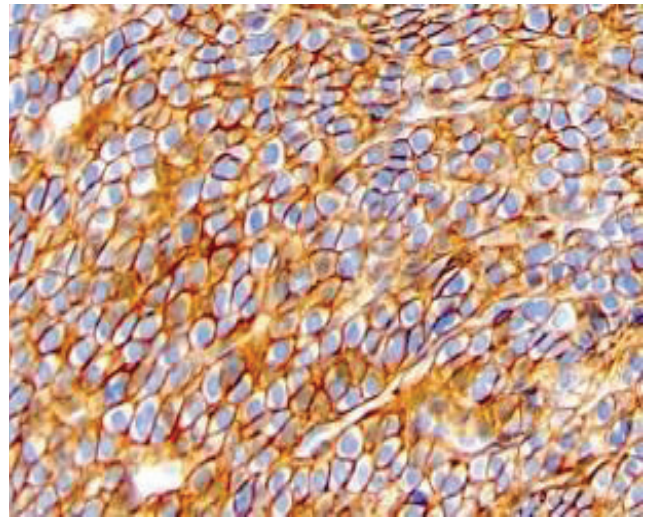


Figure 5. Collagen type IV positive in the cell membrane of neoplastic glomus cells.

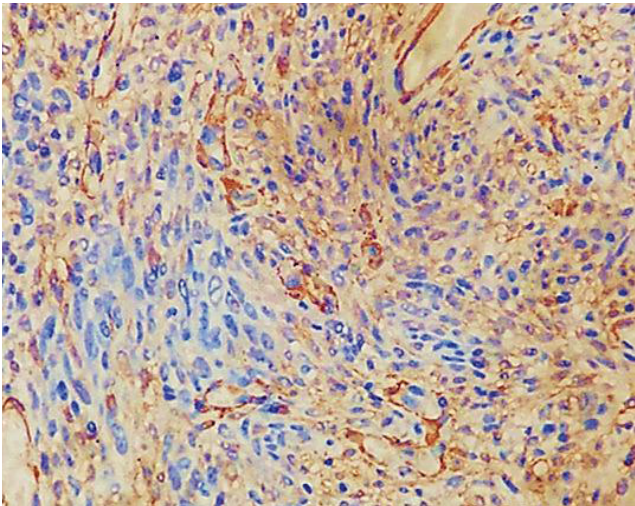


Figure 3. Glomus cells expressed positivity for Smooth Muscle α -Actine

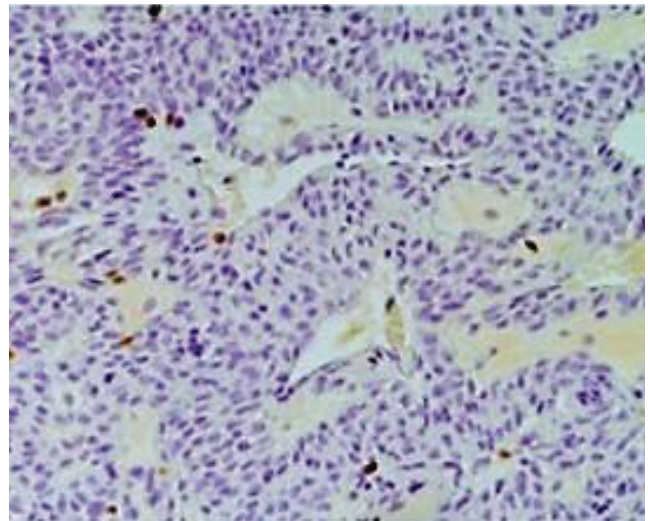


Figure 6. Ki-67 staining positive less 5 % of cells.

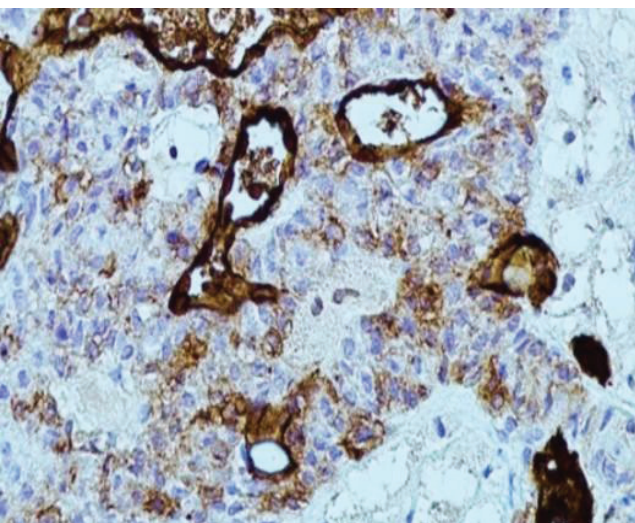


Figure 4. CD34 positive in capillary endothelial cells and lightly expressed in glomus cells in myxoid areas.

Discussion

The GTs are uncommon perivascular neoplasms of soft tissues and in some internal organs. GTs originate from glomus cells (neuromyoarterial cells) of the normal glomus apparatus present in the reticular dermis, which presents a mixture of glomus cells, blood vessels, and smooth muscle cells. GTs can also occasionally affect deep soft tissue or the internal organs, where normal glomus bodies are sparse or even absent. GT in internal organs has been reported in the stomach, intestine, genitourinary, colon, mediastinum, rectum, mesentery, liver, etc. GT is infrequently in the urinary bladder. [2, 3, 4, 7, 9]

Based on histopathological examination, GTs are classified into typical and atypical types. An atypical glomus tumor (GT) includes entities such as symplastic glomus tumors with uncertain malignant potential and malignant glomus tumors. Symplastic glomus tumors are

benign neoplasms showing striking nuclear pleomorphism in the absence of other malignant criteria. [8, 10] Depending on the relative prominence of glomus cells, vascular structures, and smooth muscle and spindle cells, the GTs are subcategorized into solid glomus tumor of the bladder (75% of cases), Glomangioma, and glomangiomyoma. [1, 2, 3, 13]

Benign GT in the urinary bladder arises secondary to truncating mutations of the globulin gene (*GLMN*) located on chromosome arm 1p21-22. [3] The glomulin is a normal protein of vascular smooth muscle during embryogenesis. In the cases of GT, the *GLMN* gene has a somatic mutation. Multiple subungual glomus tumors have been reported in neurofibromatosis type 1 (gene *NFI*). [13]

Microscopic examination of our case showed a well-circumscribed, not encapsulated neoplasm covered by a thin layer of normal urothelium with some von Brunn nests. Some areas presented an organoid or epithelioid pattern, characterized by nests of neoplastic cells with a monotonous appearance, lacking well-defined cell borders, and exhibiting abundant light eosinophilic cytoplasm. The nuclei were also devoid of nucleoli. Atypia, mitoses, intravascular growth, and necrosis were absent. In other areas, tumor cells clustered around dilated vessels. The stroma presented some myxoid and hyalinized areas.

In the immunohistochemical analysis of our case, the glomus cells did not express CK 20, CK AE1/AE3, and p63, but the neoplastic cells stained strongly positive for α -Actin Smooth Muscle and Vimentin. CD34 was positive in the capillary endothelial cells and was lightly expressed in glomus cells in myxoid areas. Finally, type IV collagen, a constituent of the basal lamina, characteristically outlines cells or small groups of cells, showing a “chicken-wire” network of matrix present between the cells.

The proliferation index with monoclonal antibody MIB-1 for the nuclear antigen Ki-67 was $< 5\%$; GTs were thought to represent hyperplasia or overgrowth of the glomus body; later, they were considered neoplastic growths or tumor-like, mesodermal developmental disorders. To date, there is agreement that they arise from glomus cells, as they demonstrate intense positive staining for α -Actin Smooth Muscle and Vimentin and negative for desmin. [2, 3, 5, 7, 10]

The biological behavior of the GT is benign. It is essential to differentiate this entity from malignant glomus tumor, which has metastatic potential, and from other bladder neoplasms. [9, 10]

The nested cell areas of our case of GT suggested a differential diagnosis with Glomangioma, glomangiomyoma, inverted papilloma, papillary urothelial neoplasm of low malignant potential, and low-grade urothelial carcinoma. [2, 5, 8]

Solid GTs are composed of solid sheets of glomus cells interrupted by vessels of varying size. In contrast, glomangiomas are less well-circumscribed and are composed of hemangioma-like vascular structures with small clusters of glomus cells in their wall. [3, 5, 7, 10]

Glomangioma (glomovenous malformation) is characterized by a somewhat poorly circumscribed proliferation of hemangioma-like vascular structures, associated with solid nests of epithelioid cells, with eosinophilic cytoplasm and enlarged, conspicuous nuclei with vesicular chromatin, variable cytologic atypia (symplastic change), and focal myxoid stroma. Mutations of the glomulin gene located on chromosome 1p22-1 are the primary gene responsible for this variant of GTs. [5, 24]

Likewise, Glomangioma resembles those solid GT and Glomangioma. However, there is

a gradual transition from round to oval glomus cells to elongated mature smooth muscle cells. [3]

Glomangiomyoma is a rare type of GT that occurs in the urinary bladder. Glomangiomyoma presents

a gradual merging of glomus cells into the smooth muscle cells and blood vessels. Microscopic examination showed nests and sheets of spindle cells resembling smooth muscle were observed. These tumor cells are located around the blood vessels and exhibit strong cytoplasmic positivity for Smooth Muscle α -Actin but are negative for cytokeratins, CD34, desmin, synaptophysin, chromogranin, and S-100 protein. The index of cell proliferation, Ki-67, is approximately 5%. [3, 5, 8]

On the other hand, Folpe et al., based on a study of 52 cases, suggested criteria and subclassified atypical GT into malignant GT (glomangiosarcoma), GT of uncertain malignant potential (GLUMP), symplastic GT, and glomangiomas. They established the criteria based on the fact that metastatic lesions were observed in 38% of tumors, fulfilling the criteria for malignant GT tumors, while metastasis was not observed in others. [5, 13, 24]

The differential diagnosis also included hemangiopericytomas. Our article showed a hemangiopericytoma vascular pattern. However, in the benign GT, the cells stained strongly upbeat for Smooth Muscle α -Actin and slightly positive for CD34 in cells into myxoid areas, in contrast with hemangiopericytomas, the oval and spindle cells of which are strongly positive for CD34 but negative for Smooth Muscle α -Actin. [3, 7, 9, 11]

The presence of monomorphic cells with central nuclei, light eosinophilic cytoplasm, and an occasional organoid growth pattern can also suggest carcinoid tumors or paragangliomas. However, the absence of staining for neuroendocrine markers (chromogranin or synaptophysin), as well as S-100 protein, ruled out these entities. Furthermore, the benign GT stained negative for desmin and caldesmon, excluding epithelioid leiomyoma and myopericytoma. [3, 7, 9, 11]

After reviewing the literature on the clinical features of these patients, the following conclusions were made:

- Bladder GT can occur in both sexes with equal frequency;
- Bladder GT mainly occurs in elderly subjects, with an age range from 40 to 85 years;
- Bladder GT patients presented with hematuria or were asymptomatic;

- d. Bladder GT patients usually exhibited no history of bladder tumors;
- e. The size and location of bladder GT were flexible (the size ranged from 3 to 65 mm diameter, and the location could be anterior, lateral, or posterolateral in the wall of the urinary bladder);
- f. 50 % of cases of GT are benign, 30 % atypical, and 20 % are malignant;
- g. Transurethral resection is the most common treatment used for benign or typical bladder tumors, whereas comprehensive treatment for malignant bladder tumors can be performed according to the patient's condition. Although these findings are meaningful, no specific clinical feature was noted.
- h. Pathological and immunohistochemical examinations are the standard methods used in the diagnosis of benign glomerular tumors (GT) of the urinary bladder. [2 - 24]

Malignant glomus tumors are sporadic. Criteria for malignancy include high nuclear grade and mitotic activity, as well as atypical mitotic figures. Glomus tumors that do not fulfill the criteria for malignancy but that

have at least one atypical feature other than pleomorphism (large size, deep location, without atypia or mitotic activity) should be diagnosed as glomus tumors of uncertain malignant potential. [3, 13]

All these factors, together with the lack of data from the literature, prompted us to recommend a close follow-up. The post-surgical recurrence rate of GT is approximately 10 %, and malignant transformation after recurrence or dedifferentiation, although exceptional, has been described. [2, 3, 6]

Conclusions:

GTs arising in the bladder are extremely rare. It is challenging to diagnose bladder GTs based on their clinical features. The gold standard method for diagnosing GT is histopathology and immunohistochemical examination. Transurethral resection is the most common treatment used for benign or atypical bladder GT. However, it should also be considered in the differential diagnosis of bladder neoplasms.

COI Statement: This paper has yet to be submitted in parallel, presented fully or partially at a meeting, podium, or congress, published, or submitted for consideration beforehand.

This research received no specific funding from the public, commercial, or non-profit sectors. The authors declare that they, their relatives, or next of kin have no financial relationships with external companies that could be considered relevant or minor.

Disclosure: The authors declared no conflict of interest. No funding was received for this study.

References

1. WHO Classification of Tumours. Soft tissue and bone tumors (WHO Classification of Tumors series, 5th ed. Vol. 3). International Agency for Research on Cancer; 2020.
2. Gombos Z, Zhang PJ. Glomus tumor. Arch Pathol Lab Med. 2008;132(9): 1448–1452. 1008
3. Sergio Antonio Tripodi, MD; Bruno Jim Rocca, MD; Vasileios Mourmouras, MD; Gabriele Barbanti, MD; Maurizio Colecchia, MD; Maria Raffaella Ambrosio, MD. Benign Glomus Tumor of the Bladder. Arch Pathol Lab Med. July 2013; 137: 1005–1008.
4. Shim HS, Choi YD, Cho NH. Malignant glomus tumor of the urinary bladder. Arch Pathol Lab Med. 2005;129(7):940–942.
5. Chalise S, Jha A, Neupane PR. Glomangiomyoma of uncertain malignant potential in the urinary bladder: a case report. *JNMA J Nepal Med Assoc.* 2021;59(239):719–722.
6. Ai J, Zhang S, Qian Y, Kang L, Zhang L, Zhao J. Radiotherapy and Anrotinib in Malignant Glomus Tumor of Bladder: A Case Report and Literature Review. *Cancer Biother Radiopharm.* 2024;39(4):318-21.
7. Cheng L, Tretiakova M. Glomus tumor. Pathology Outlines. com website. May 24, 2025.
8. Waters LL, Zhai QH, Buie JS, Miller R, Pumphrey JA, Wu S. Atypical glomus tumor of uncertain malignant potential in the urinary bladder. *Pathol Lab Med Int.* 2010;10(2):141–144.
9. Chen L, Lai B, Su X, Wang J. Unusual glomus tumor of the bladder: a rare case report and literature review. *BMC Urol.* 2021;21(1):66.
10. Palmisano F, Gadda F, Spinelli MG, Maggioni M, Rocco B, Montanari E. Symplastic glomus tumor of the urinary bladder treated by robot-assisted partial cystectomy: a case report and literature review. *Urologia.* 2018; 85 (3): 130 – 132.
11. Xiaoling Ma, Chenglong Pan, Anqi Xu, Xiaojing Guo, Ynafei Yao, Ziqi Li, Youmei Zhao, Chunyan Wang, Zhi Nie. Benign Glomus Tumor of the Urinary Bladder: A Case Report and Literature Review. *Int J Surg Pathol.* 2024 Dec 9
12. Katia Ramos Moreira Leite, Ana Carolina Armiliato Bogoevich, Ivan Borin Selegatto, Thiago José Penachim, Wilmar Azal Neto. Glomus tumors in the urinary tract: a rare case and literature review. *International Journal of Pathology,* Vol. 22 No. 3, Jul - Sept 2024.
13. Folpe AL, Guillou L. Tumor of perivascular cells. In: *Bone and Soft Tissue Pathology.* 9th ed. Philadelphia, PA: Saunders-Elsevier; 2010:153-155.
14. Herawi M, Parwani AV, Edlow D, Smolev JK, Epstein JI. Glomus tumor of renal pelvis: a case report and review of the literature. *Hum Pathol.* 2005;36(3): 299–302.
15. Sasaki K, Bastacky SI, Hrebinko RL, Parwani AV, Zynger DL. Glomus tumor of the kidney: case report and literature review. *Int J Surg Pathol.* 2011; 19 (3) 393–397.
16. Ramsay S, Chan G, Zimmerman WB, Chee J. Glomus tumour of the male urethra: an unusual diagnostic. *BMJ Case Rep.* 2019; 12 (11): e 232261.
17. Sun Z, Sun F, Yu C, Xiao H, Xu Q, Gao B, et al. Malignant glomus tumor of prostate: A case Report. *Frontiers in oncology.* 2023; 13: 1121307.

18. Tullie S, Quraishi MK, Karawita T, Anjarwalla S. Rare presentation of a testicular glomus tumor. *BMJ Case Rep.* 2019; 12 (11): e 230935.
19. Fejes R, Gyorgyev S, Góg C, Krenács L, Zombori T, Széll ZE, Balajthy Z, Pancsa T, Simonka Z. Gastric glomus tumor with uncertain malignant potential: case report of a rare cause of upper gastrointestinal bleeding. *World J Surg Oncol.* 2024 Nov 13; 22 (1): 299 - 303.
20. Zirona A, Grotz TE, Folpe AL, Thiels CA. Gastrointestinal Glomus Tumors: A single Institution, 20 – year Retrospective study. *Journ. Surg Res.* 2023 Mar;283: 982 - 991.
21. Elkrinawi R, Usta E, Baumbach H, Franke UF. Late recurrence of a cardiac glomus tumor. *Thorac Cardiovasc Surg.* 2012; 60 (4): 305 – 306.
22. Liu Y, Wu R, Yu T, Cao Y, Lu L. Malignant glomus tumor of the thyroid gland: a case report. *Journ. Int Med Res.* 2019; 47 (6): 2723 – 2727.
23. De Bruin AF, Verhoef C, den Bakker MA, van Geel A. Glomus tumor of the mesentery with atypical features: a case report. *International Journ. Surg. Pathology.* 2008; 16 (4): 440–442.
24. Mosquera J. M, Sboner A, Lei Zhang, et al. Novel MIR143-NOTCH fusion in Benign and Malignant Glomus Tumors. *Cancer* 2013, Sep 2; 52 (11): 1075 - 1078