

Non-surgical Treatment of Metastatic Liver Tumors with Microwave Ablation.

Ilirian Laçi^{1*}, Alketa Spahiu².

Received: 14 June 2022 / Accepted: 07 July 2022 / Published online: 20 July 2022

This article is published with open access at <https://journal.astes.org.al>

© The author(s) 2022. © The Albanian Journal of Trauma and Emergency Surgery is an Open Access Journal. All articles are distributed under the terms of the Creative Commons Attribution Non-Commercial License: <http://creativecommons.org/licenses/by-nc> which permits unrestricted non-commercial use, distribution, and reproduction in any medium provided the original work is properly cited.

Abstract

With all the measures taken, the trend of liver cancer cases has increased worldwide, as a consequence, this is accompanied by an increase in mortality by 43% (10.3 per 100,000 in 2016 (USA)) [1, 2].

Liver cancer is also associated with the lowest 5-year survival rate among all types of cancer (19%) [1].

Liver cancer (including intrahepatic bile duct cancer) was the ninth leading cause of cancer death in 2000 and rose to sixth in 2016 [3].

This shows that the identification of safe and effective treatments for liver cancer is urgent now.

Microwave ablation is a thermal ablation modality that has particular applicability in treating hepatic malignancies primary tumors or metastases. Microwaves can generate very high temperatures in short time periods, potentially leading to improved treatment efficiency in larger ablation zones.

We will show a patient male 55 years old. Post-surgery of colon cancer 6 months ago. Normal exam. There is a liver metastasis in the right lobe subcapsular 22mm. The patient was a good candidate for MWA.

Conclusions

MWA is an effective and safe alternative in patients/tumors that are not suitable for resection. Survival and recurrence outcomes after MWA are significantly improved with significantly shorter hospital stays and operative times, with little or no intraoperative blood loss and minor complications. Its use should be extended more and more in the field of treatment of these patients depending on the therapeutic indications

Keywords: microwave, ablation, liver tumors, liver metastases

Introduction:

Numerous techniques have been developed to kill tumor cells including heating, freezing, radiation, chemotherapy, shutting off the blood supply to the tumor, injection of caustic agents directly to the tumor, as well as various combinations of these.[4]

Hindu and Greek healers used heat clinically for hemostasis since ancient times. Hippocrates said that “those diseases that medicine cannot cure, the knife (surgery) cures; what the knife (surgery) cannot heal, fire heals.” [5]

While most of these were introduced in the late 20th century, at least one dates to the 19th century.

The basic technique for radiofrequency RFA ablation was described a century ago by D’Arsonval, who, in 1891, first demonstrated that when RF waves passed through tissue, they caused an increase in tissue temperature [6]. In the early 1900s, RF was used relatively little for medical purposes [7].

In 1910 Beer [6] described a new method for treating bladder neoplasms using cauterization through a cystoscopy.

However, it was not widely used for medical applications until the introduction of the Bovie knife in 1928 by Cushing and Bovie instrument which can be used

Original article, no submission or publication in advance or in parallel

*** Corresponding author:**

Ilirian Laçi MD, PhD

✉ ilirianlaci@yahoo.com

1 Department of Radiology and Nuclear Medicine, University Hospital Center “Mother Theresa” Tirana, Albania

2 Nephrologist, Polyclinic of Specialties No. 3, Tirana, Albania

either for cauterization or for cutting tissue by changing the radiofrequency current. [9], Heat therapy is based on the data of Coley et al. that tumor cells are more sensitive to heat than normal cells. [10]

The needle shaft does not produce heat, on the contrary, heat is produced in the tissue and this leads to coagulation and cell necrosis. Thermal ablation techniques were described in 1995 for the first time using animal lung tumor models and then in the 2000s in humans.[11]

Microwave ablation has emerged as a newer ablation modality and addition to the range of care for minimally invasive cancers.[12]

The advantages of microwave ablation over other heat-based modalities, such as radiofrequency or laser ablation, include a larger and faster volume of tissue heating than with a single application.

Unlike radiofrequency ablation, MWA does not rely on an electrical circuit allowing the simultaneous use of multiple applicators.[13]

Microwave ablation (MWA) is a form of thermal ablation used in interventional radiology to treat cancer, which uses electromagnetic waves in the microwave energy spectrum (300 MHz to 300 GHz) to produce the effect of tissue heating.

Oscillations of polar molecules produce frictional heating, ultimately generating tissue necrosis within solid tumors. It is generally used to treat and/or reduce solid tumors in patients who are non-surgical candidates. [14]

Thermal microwave ablation (MWA) is an emerging technique that shares many characteristics with RFA. Indeed, the technical features of the procedure are almost identical to those of RFA. The differences arise from the physical phenomenon used to generate heat.[15]

While RFA benefits from resistive heating generated by electrical current, MWA refers to devices that use physical waves with frequencies higher than or equal to 900 MHz. [16]

Heat is produced by the agitation of polar molecules, such as water molecules, caused by microwave pulses; ionic polarization accounts for a much smaller fraction of energy deposition.[17]

MWA is primarily based on two frequency categories: 915 and 2450 MHz, 2450 MHz being the most commonly used while 915 MHz may present deeper tissue penetration, thus potentially larger ablation areas.[18]

MWA presents several theoretical advantages over RFA: it can provide larger areas of coagulation necrosis in shorter times since MWA is less affected by the protection of adjacent tissues provided by vaporization and carbonization, and is also much less disturbed by the heat absorption effect. [19]

MWA works by producing electromagnetic waves in the microwave energy spectrum, which create heat around the needle, which heats and destroys cancer cells. Heat closes small blood vessels and lessens the risk of bleeding. The dead tumor cells are gradually replaced by scar tissue. [20]

The medical team should use ultrasound, computed tomography, or magnetic resonance imaging to help guide the needle electrode to the tumor.

Ablation uses one of three methods: Surgery; Percutaneous, in which the doctor inserts needle electrodes through the skin and into the site of the tumor; Laparoscopic, in which needle electrodes within a thin, plastic tube are threaded through a small hole in the skin. [21]

Each process takes about 10 to 30 minutes, with the additional time needed if multiple ablations are performed. The entire procedure usually takes one to three hours.

Procedure

Percutaneous image-guided thermal ablation has become an accepted treatment method for many tumors in the liver, kidney, lung, and bone [22].

In the liver, thermal ablation is considered first-line therapy for small (< 3 cm) hepatocellular carcinoma in the setting of cirrhosis and second-line therapy for the treatment of medically or surgically inoperable oligometastatic colorectal metastases [23].

Percutaneous ablation has also been used successfully to treat benign hepatic tumors, such as giant cavernous hemangiomas and hepatocellular adenomas. [24, 25]

High-powered microwave ablation systems have shown the potential to create larger ablation zones than radiofrequency ablation devices, with similar applicator size and shape [16, 17].

Percutaneous ablation of primary and secondary liver tumors has become an important treatment alternative and is likely to soon occupy a more central role in the management of all patients with hepatocellular carcinoma (HCC) and liver metastases from colorectal cancer (CRC) [26].

Microwave ablations produce heat. Polar molecules in the tissue are forced to continuously realign with the oscillating electric field, in this way increasing the temperature of the tissue. Tissues with a high percentage of water (solid organs and tumors) are most conducive to this type of heating. [27 -29]

Microwave radiates to tissue through an interstitial antenna, direct heating of a volume of tissue around the antenna destroys the tissue in that area.

MWAs are able to spread and effectively heat several types of tissue, even those with low electrical conductivity, high resistance, or low thermal conductivity. [28, 29]

Multiple microwave antennas can be powered simultaneously to take advantage of thermal synergy when placed in proximity or widely spaced to ablate several tumors simultaneously. [30-33]

Microwave ablation is the ability for antennas to be positioned and phased to exploit the overlap of the electromagnetic field energy.[32]

Microwave reflected power and shaft heating, short relatively low-power ablation cycles. MWA can use multiple probes. Systems of MWA with are able to decrease the applicator size and deliver higher power.

Reports on the safety and efficacy of hepatic microwave ablation have focused on the overall safety profile. [33, 34] In some cases, the sequela of diaphragmatic injury or thermal ablation may happen which depends on the position of the tumor.




Figure 1 - The needle for percutaneous insertions

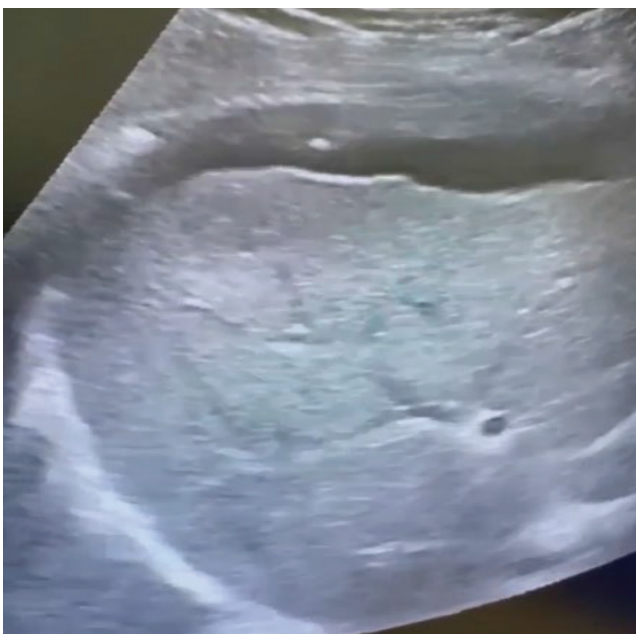
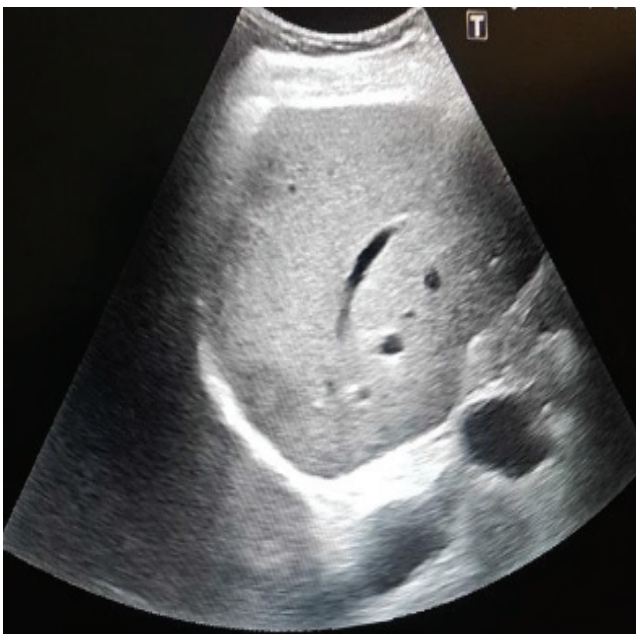


Figure 2, 3 - The needle is in sub-diaphragmic space.

Our Experience

Patient male 55 years old. Post-surgery of colon cancer 6 month ago. Normal exam.

There is e liver metastasis in right lobe subcapsular 22mm.

Patient is a good candidate for MWA. Below is tumor in ultrasound and MWA electrode.

We use the Hydro-dissection by using Sol NaCl 0,9 % -500 ml subcapsular area, to protect diaphragm. (Fig.1, 2, 3)

CT scan one month after procedure treatment, there is lesion without contrast in parenchymal contrast phase. Tumor ablated. (Fig.7).

Tumor is image post completely ablated tumor. (Fig. 7)

Patient was day hospital. Treated him with 2 g cephalosin iv. In follow up after the tumor is only a cystic lesion. MWA is a good way of treatment in patient indicated for this treatment.

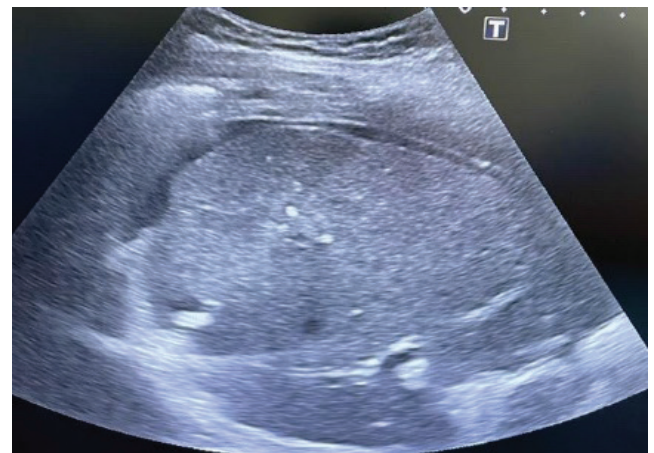


Figure 4 - Electrode is in the central of the tumor, early phase.

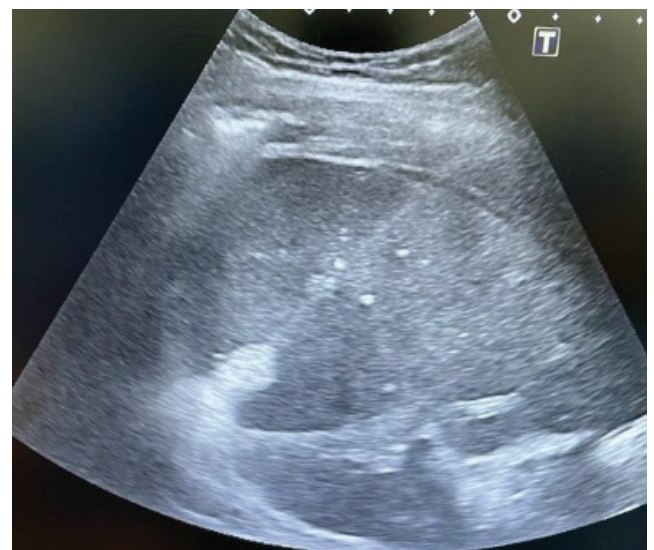

Figure 5 - Electrode is in the central of the tumor, late phase

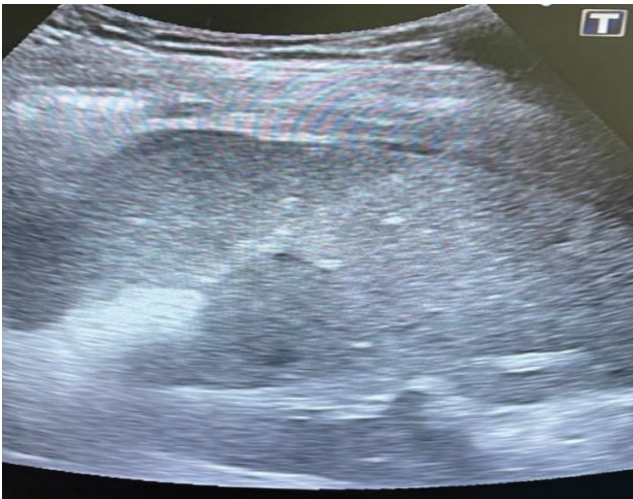


Figure 6 - The end of procedure, the tumor is ablated.

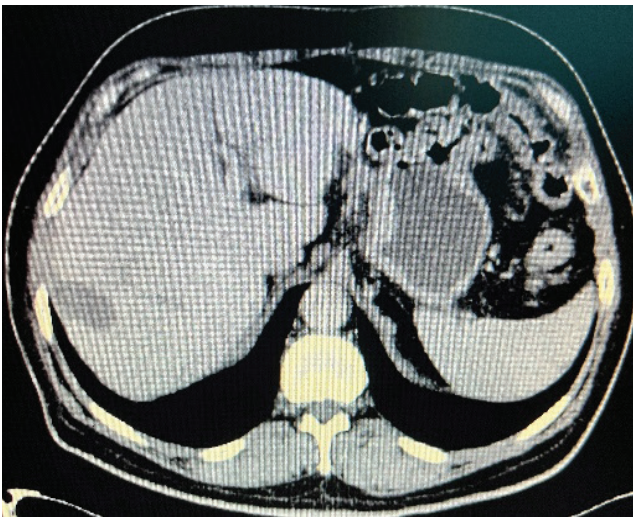


Figure 7- CT scan one month after procedure treatment, there is lesion without contrast in parenchymal contrast phase. Tumor ablated.

Discussion

Microwave ablation can be an effective treatment for primary liver cancer and for cancers that have spread to the liver in select patients whose liver tumors are unsuitable for surgical resection.[35]

In most studies, more than half of the liver tumors treated by ablation have not recurred. The success rate for completely eliminating small liver tumors is greater than 85 percent.[36]

Treatment-related serious complications are infrequent and discomfort is less than surgery.

Ablation may be used repeatedly to treat recurrent liver tumors. [35]

The percutaneous method of ablation, in which needles are inserted through the skin, is minimally invasive, produces few complications, and does not require hospital admission.[37]

Ablation is a relatively quick procedure and recovery is rapid. Chemotherapy may resume almost immediately in patients who need it.[37]

Ablation is less expensive than other treatment options.

No surgical incision is necessary—only a small nick in the skin that does not need stitches.[37]

It is important to note that MWA, like RFA, can be part of combined treatments and can cause a synergistic effect with transarterial chemoembolization (TACE). It has been shown that interruption of hepatic blood flow can increase the area of thermal ablation. [38]

Microwave ablation (MWA) are widely accepted technique to eliminate colorectal liver metastases. Although previous studies labeled thermal ablation inferior to surgical resection. Thermal ablation compared with hepatic resection in patients with at least one resectable and ablative colorectal liver metastases and no extrahepatic disease.[39]

In general, all ablative techniques show a variety of results in terms of complete ablation, complications, and treatment time, making it difficult to analyze the results and draw conclusions.

More studies and experience are needed using identical technique protocols to improve data (obtain complete pathologic ablation in all patients), standardize techniques, and obtain the best ablative technique in each field. [40].

In addition, comparative studies are necessary to then compare the ablative techniques with each other to decide which one is more promising and cost-effectiveness analysis is required.

Lack of complete histopathological ablation may be due to several factors, lack of immobilization or lack of adequate anesthesia resulting in patient movement and inefficient treatment or a wrong choice in imaging direction. [41].

Immobilization is required to minimize movement caused by discomfort due to patient position, breathing, treatment-induced pain, or other body movements. Patient movement can also be reduced by increasing the level of anesthesia given to the patient. However, simple local anesthesia may not be effective enough to use the technique optimally. [42].

CT is able to provide good spatial resolution, but it also cannot visualize flow within vessels or temperature changes in real-time. [42].

Conclusions

MWA is an effective and safe alternative in patients/tumors that are not suitable for resection. Survival and recurrence outcomes after MWA are significantly improved with significantly shorter hospital stays and operative times, with little or no intraoperative blood loss and minor complications. Its use should be extended more and more in the field of treatment of these patients depending on the therapeutic indications.

COI Statement: This paper has not been submitted in parallel. It has not been presented fully or partially at a

meeting or podium or congress. It has not been published nor submitted for consideration beforehand.

This research received no specific grant from any funding agency in the public, commercial, or non-profit sectors. There are no relevant or minor financial relationships from authors, their relatives or next of kin with external companies.

Disclosure: The authors declared no conflict of interest. No funding was received for this article.

References

- American Cancer Society. Cancer Facts & Figures 2018 [Available from: <https://www.cancer.org/research/cancer-facts-statistics/all-cancer-facts-figures/cancer-facts-figures-2018.html>].
- Xu J. Trends in Liver Cancer Mortality Among Adults Aged 25 and Over in the United States, 2000-2016. NCHS Data Brief. 2018 Jul;(314):1-8. PMID: 30044212.
- Hales CM, Carroll MD, Fryar CD, Ogden CL. Prevalence of obesity among adults and youth: United States, 2015–2016. NCHS Data brief, no 288. Hyattsville, MD: National Center for Health Statistics. 2017.
- McGahan, J.P., van Raalte, V.A. (2005). History of Ablation. In: vanSonnenberg, E., McMullen, W.N., Solbiati, L., Livraghi, T., Müeller, P.R., Silverman, S.G. (eds) Tumor Ablation. Springer, New York, NY. https://doi.org/10.1007/0-387-28674-8_1
- Adams F. *Genuine works of Hippocrates*. William Wood and Company; New York: 1886. translator. [Google Scholar] [Ref list]
- D'Arsonval M. A. (1891). A. Referate I. Niederösterreich. *Oesterr. Botan. Z.* 41, 283–286. 10.1007/bf01790749 [CrossRef] [Google Scholar] [Ref list]
- Clark WL. Oscillatory desiccation in the treatment of accessible malignant growths and minor surgical conditions. *J Adv Ther.* 1911;29:169–183. [Google Scholar] [Ref list]
- Beer E. Landmark article May 28, 1910: Removal of neoplasms of the urinary bladder. By Edwin Beer. *JAMA* 1983; 250: 1324-1325. [PubMed] [Google Scholar] [Ref list]
- Cushing H., Bovie W. T. (1928). Electro-surgery as an Aid to the Removal of Intracranial Tumors. *Surg. Gynecol. Obstet.* 47, 751–784.
- Coley WB. The treatment of malignant tumors by repeated inoculations of erysipelas, with a report of ten original cases. *Am J Med Sci.* 1893;105:487–492. [Google Scholar] [Ref list]
- Goldberg SN, Gazelle GS, Compton CC, McLoud TC (1995). Radiofrequency Tissue Ablation in the Rabbit Lung: Efficacy and Complications. *Acad Radiol* 2(9).
- Dupuy DE, Zagoria RJ, Akerley W, Mayo-Smith WW, Kavanagh PV, Safran H (2000). Percutaneous radiofrequency ablation of malignancies in the lung. *AJR Am J Roentgenol* 174(1).
- Dupuy DE (2009). Microwave Ablation Compared with Radiofrequency Ablation in Lung Tissue – Is Microwave Not Just for Popcorn Anymore? *Radiology* 251(3).
- Lubner MG, Brace CL, Hinshaw JL, Lee FT Jr. Microwave tumor ablation: mechanism of action, clinical results, and devices. *J Vasc Interv Radiol.* 2010 Aug;21(8 Suppl): S192-203. doi: 10.1016/j.jvir.2010.04.007. PMID: 20656229; PMCID: PMC3065977.
- Izzo F, Granata V, Grassi R, Fusco R, Palaia R, Delrio P, Carrafiello G, Azoulay D, Petrillo A, Curley SA. Radiofrequency Ablation and Microwave Ablation in Liver Tumors: An Update. *Oncologist.* 2019 Oct;24(10): e990-e1005. doi: 10.1634/theoncologist.2018-0337. Epub 2019 Jun 19. PMID: 31217342; PMCID: PMC6795153. C.J.
- Simon, D.E. Dupuy, W.W. Mayo-Smith Microwave ablation: principles and applications *Radiographics*, 25 (October (Suppl. 1)) (2005), pp. S69-S83
- C.L. Brace Radiofrequency and microwave ablation of the liver, lung, kidney, and bone: what are the differences? *Curr Probl Diagn Radiol*, 38 (May–June (3)) (2009), pp. 135-143
- M. Tanaka, M. Sato Microwave heating of water, ice, and saline solution: molecular dynamics study *J Chem Phys*, 126 (January (3)) (2007), p. 034509
- C.J. Simon, D.E. Dupuy, W.W. Mayo-Smith Microwave ablation: principles and applications *Radiographics*, 25 (October (Suppl. 1)) (2005), pp. S69-S83
- Fallahi H, Prakash P. Antenna Designs for Microwave Tissue Ablation. *Crit Rev Biomed Eng.* 2018;46(6):495-521. doi: 10.1615/CritRevBiomedEng.2018028554. PMID: 30806212; PMCID: PMC6391890.
- Conor J. Walsh, Alexander H. Slocum, and Rajiv Gupta “Preliminary evaluation of robotic needle distal tip repositioning”, *Proc. SPIE* 7901, Energy-based Treatment of Tissue and Assessment VI, 790108 (22 February 2011); <https://doi.org/10.1117/12.876604>
- Livraghi T, Solbiati L, Meloni MF, Gazelle GS, Halpern EF, Goldberg SN. Treatment of focal liver tumors with percutaneous radio-frequency ablation: complications encountered in a multicenter study. *Radiology* 2003; 226:441–451
- Gervais DA, Goldberg SN, Brown DB, Soulen MC, Millward SF, Rajan DK. Society of Interventional Radiology position statement on percutaneous radiofrequency ablation for the treatment of liver tumors. *J Vasc Interv Radiol* 2009; 20(suppl 7):S342–S347
- van der Sluis FJ, Bosch JL, Terkivatan T, de Man RA, Ijzermans JN, Hunink MG. Hepatocellular adenoma: cost-effectiveness of different treatment strategies. *Radiology* 2009; 252:737–746
- Sharpe EE 3rd, Dodd GD 3rd. Percutaneous radiofrequency ablation of symptomatic giant hepatic cavernous hemangiomas: report of two cases and review of literature. *J Vasc Interv Radiol* 2012; 971–975
- Hines-Peralta A U, Pirani N, Clegg P. et al. Microwave ablation: results with a 2.45-GHz applicator in ex vivo bovine and in vivo porcine liver. *Radiology.* 2006;239(1):94–102.
- Shock S A, Meredith K, Warner T F. et al. Microwave ablation with loop antenna: in vivo porcine liver model. *Radiology.* 2004;231(1):143–149.
- Lu M D, Xu H X, Xie X Y. et al. Percutaneous microwave and radiofrequency ablation for hepatocellular

- carcinoma: a retrospective comparative study. *J Gastroenterol.* 2005;40(11):1054–1060.
29. Schramm W, Yang D, Haemmerich D. Contribution of direct heating, thermal conduction and perfusion during radiofrequency and microwave ablation. *Conf Proc IEEE Eng Med Biol Soc.* 2006; 1:5013–5016.
 30. Tremblay B S, Douple E B, Ryan T P, Hoopes P J. Effect of phase modulation on the temperature distribution of a microwave hyperthermia antenna array in vivo. *Int J Hyperthermia.* 1994;10(5):691–705.
 31. Magin R L, Peterson A F. Noninvasive microwave phased arrays for local hyperthermia: a review. *Int J Hyperthermia.* 1989;5(4):429–450.
 32. Clibbon K L, McCowen A, Hand J W. SAR distributions in interstitial microwave antenna arrays with a single dipole displacement. *IEEE Trans Biomed Eng.* 1993;40(9):925–932.
 33. Camart J C, Dubois L, Fabre J J, Vanloot D, Chive M. 915 MHz microwave interstitial hyperthermia. Part II: Array of phase-monitored antennas. *Int J Hyperthermia.* 1993;9(3):445–454.
 34. Durick N A, Laeseke P F, Broderick L S. et al. Microwave ablation with triaxial antennas tuned for lung: results in an in vivo porcine model. *Radiology.* 2008;247(1):80–87.
 35. Glassberg MB, Ghosh S, Clymer JW, Wright GWJ, Ferko N, Amaral JF. Microwave ablation compared with hepatic resection for the treatment of hepatocellular carcinoma and liver metastases: a systematic review and meta-analysis. *World J Surg Oncol.* 2019 Jun 10;17(1):98. doi: 10.1186/s12957-019-1632-6. PMID: 31182102; PMCID: PMC6558848.
 36. Stattner S, Jones RP, Yip VS, Buchanan K, Poston GJ, Malik HZ, et al. Microwave ablation with or without resection for colorectal liver metastases. *Eur J Surg Oncol.* 2013;39(8):844–849. doi: 10.1016/j.ejso.2013.04.005. [PubMed] [CrossRef] [Google Scholar] [Ref list]
 37. Peek MCL, Douek M. Ablative techniques for the treatment of benign and malignant breast tumours. *J Ther Ultrasound.* 2017 Jul 3;5:18. doi: 10.1186/s40349-017-0097-8. PMID: 28680636; PMCID: PMC5494757.
 38. Puijk, R.S., Ruarus, A.H., Vroomen, L.G.P.H. et al. Colorectal liver metastases: surgery versus thermal ablation (COLLISION) – a phase III single-blind prospective randomized controlled trial. *BMC Cancer* 18, 821 (2018). <https://doi.org/10.1186/s12885-018-4716-8>
 39. Dupuy DE, Liu D, Hartfeil D, et al. Percutaneous radiofrequency ablation of painful osseous metastases: a multicenter American College of Radiology Imaging Network trial. *Cancer* 2010; 116:989–997
 40. Thanou M, Gedroyc W. MRI-Guided Focused Ultrasound as a New Method of Drug Delivery. *J Drug Deliv.* 2013;2013:616197. doi: 10.1155/2013/616197. [PMC free article] [PubMed] [CrossRef] [Google Scholar] [Ref list]
 41. Haar GT, Coussios C. High intensity focused ultrasound: physical principles and devices. *Int J Hyperthermia.* 2007;23(2):89–104. doi: 10.1080/02656730601186138. [PubMed] [CrossRef] [Google Scholar] [Ref list]
 42. Li S, Wu PH. Magnetic resonance image-guided versus ultrasound-guided high-intensity focused ultrasound in the treatment of breast cancer. *Chin J Cancer.* 2013;32(8):441–452. doi: 10.5732/cjc.012.10104. [PMC free article] [PubMed] [CrossRef] [Google Scholar] [Ref list] *Radiol* 2012; 35:868–874.